



## [Medicina Legal de Costa Rica](#)

On-line version ISSN 2215-5287 Print version ISSN 1409-0015

**Med. leg. Costa Rica vol.39 n.2 Heredia Sep./Dec. 2022**

### INVESTIGACIÓN ORIGINAL

## Reliability and validity between two instruments for measuring spine sagittal parameters in adolescents with idiopathic scoliosis during various stages of growth

## Confiabilidad y validez entre dos instrumentos para medir parámetros sagitales de la columna vertebral en adolescentes con escoliosis idiopática durante varias etapas de crecimiento

Ariane Verttú Schmidt<sup>1</sup>

Rodrigo Mantelatto Andrade<sup>2</sup> <sup>3</sup>

Neil Ferreira Novo<sup>1</sup>

Ana Paula Ribeiro<sup>1</sup> <sup>3</sup>

 <http://orcid.org/0000-0002-1061-3789>



<sup>1</sup> Health Science Post-Graduate Department, School Medicine, Biomechanics and Musculoskeletal Rehabilitation Laboratory, University Santo Amaro, Sao Paulo, Brazil.

<sup>2</sup> Spine Group, Clinical Center in Scoliosis, São Paulo, SP, Brazil.








<sup>3</sup> University of Sao Paulo, Physical Therapy Department, School of Medicine, Sao Paulo, Brazil.

#### Services on Demand

##### Journal

-  SciELO Analytics
-  Google Scholar H5M5 (2018)

##### Article

-  English (pdf)
-  Article in xml format
-  Article references
-  How to cite this article
-  SciELO Analytics
-  Automatic translation
-  Send this article by e-mail

##### Indicators

##### Related links

##### Share

-  More
- More

 Permalink

## ABSTRACT

### Introduction:

Adolescent idiopathic scoliosis (AIS) is the most common and severe spinal deformity, which affects children and adolescents in the stage of neuromotor development and skeletal maturity of the sagittal curvatures of the spine. The literature presents several radiation-free instruments to assess and monitor the progression of scoliotic curvature angles in the AIS. However, the reliability and validity of the inclinometer at different stages of growth in relation to X-ray parameters has not been understood to date.

**Objective:**

To evaluate the reliability of the inclinometer and its validity with the X-ray exam on the sagittal parameters of the spine in the early and late growth stages of adolescents with AIS.

**Methods:**

A cross-sectional study was conducted with 39 adolescents with AIS who were divided into two groups: the initial growth phase (10-13 years) and the late growth phase (14-18 years). The evaluated sagittal parameters of the spine were the angle of the thoracic kyphosis and the angle of the lumbar lordosis, both measured by the X-ray image examination and the inclinometer.

**Results:**

The inclinometer showed excellent inter- and intra-examiner reliability for the different growth phases, early and late, with a strong association with the X-ray (gold standard;  $r = 0.84$ ;  $p = 0.308$  and  $r = 0.75$ ;  $p = 0.517$ ). The angle of lumbar lordosis was different between the inclinometer and X-ray instruments in the early and late stages of growth ( $p < 0.001$ ), with moderate reliability and a less significant correlation with the gold standard of radiography ( $r = 0.38$ ;  $p = 0.001$  and  $r = 0.49$ ;  $p = 0.024$ ).

**Conclusion:**

The inclinometer showed excellent reliability and validity for the sagittal parameter of thoracic kyphosis in the early and late stages of growth. The angle of lumbar lordosis measured by inclinometer proved to be of moderate reliability and weak validity when considering the phases of skeletal growth, showing it to be an inefficient instrument for monitoring the lumbar scoliotic curvature for AIS.

**Key words:** Scoliosis; adolescents; growth; X-ray; inclinometer

---

**RESUMEN****Introducción:**

La escoliosis idiopática del adolescente (EIA) es la deformidad espinal más común y severa, que afecta a niños y adolescentes en la etapa de desarrollo neuromotor y madurez esquelética de las curvaturas sagitales de la columna. La literatura presenta varios instrumentos libres de radiación para evaluar y monitorear la progresión de los ángulos de curvatura escolióticos en el AIS. Sin embargo, hasta la fecha no se ha entendido la fiabilidad y validez del inclinómetro en diferentes etapas de crecimiento en relación con los parámetros de rayos X.

**Objetivo:**

Evaluar la confiabilidad del inclinómetro y su validez con el examen de rayos X sobre los parámetros sagitales de la columna vertebral en las etapas de crecimiento temprano y tardío de adolescentes con EIA.

**Materiales y métodos:**

Se realizó un estudio transversal con 39 adolescentes con EIA que se dividieron en dos grupos: la fase de crecimiento inicial (10-13 años) y la fase de crecimiento tardío (14-18 años). Los parámetros sagitales de la columna evaluados fueron el ángulo de la cifosis torácica y el ángulo de la lordosis lumbar, ambos medidos por el examen de imagen de rayos X y el inclinómetro.

**Resultados:**

El inclinómetro mostró una excelente confiabilidad inter e intraexaminador para las diferentes fases de crecimiento, temprana y tardía, con una fuerte asociación con la radiografía (estándar de oro;  $r = 0.84$ ;  $p = 0.308$  y  $r = 0.75$ ;  $p = 0,517$ ). El ángulo de lordosis lumbar fue diferente entre el inclinómetro y los instrumentos de rayos X en las etapas tempranas y tardías del crecimiento ( $p < 0,001$ ), con confiabilidad moderada y una correlación menos significativa con el estándar de oro de la radiografía ( $r = 0,38$ ;  $p = 0,001$  y  $r = 0,49$ ;  $p = 0,024$ ).

## Conclusión:

El inclinómetro mostró excelente confiabilidad y validez para el parámetro sagital de cifosis torácica en etapas tempranas y tardías de crecimiento. El ángulo de lordosis lumbar medido por inclinómetro demostró ser de confiabilidad moderada y validez débil al considerar las fases de crecimiento esquelético, mostrándose como un instrumento ineficiente para monitorear la curvatura escoliótica lumbar para EIA.

**Palabras claves:** Escoliosis; adolescentes; crecimiento; rayos X; inclinómetro

---

## INTRODUCTION

Currently, adolescent idiopathic scoliosis (AIS) is the most common and severe spinal deformity, which affects children and adolescents in the stage of neuromotor development and skeletal maturity of the sagittal curvatures of the spine ([1](#)). AIS is defined as a three-dimensional deformity of the spine characterized by lateral inclination and axial rotation of the vertebral bodies, with an angle equal to or greater than 10 degrees, as measured using the Cobb method ([2](#)). Worldwide, AIS affects about 2% of the population, but this can change according to the latitude of the country or region ([1,4](#)). The prevalence of AIS is higher in females, with 13 and 14 years being the ages most affected ([5](#)).

According to scientific evidence, the development of idiopathic scoliosis can occur in childhood and worsen in the adolescence period, with its most significant moment of progression associated with the growth spurt in the adolescence period. Its progression is strongly related to sex, age at onset, and the degree of spine angulation ([6](#)). The consequences of the progression of scoliotic curvature can vary from constant pain along the spine to functional impairments, such as reduced motor coordination, body balance, and changes in walking. The aesthetic changes of the spine, together with the physical-functional changes, such as social and psychological implications for the adolescent ([7](#)).

The progression of scoliotic curvature can be prevented or better controlled through an accurate and reliable prognosis for adolescents when combined with adolescents' capacity for growth and skeletal maturity([8,9](#)). It is known that AIS progresses in the phases of more accelerated growth, also known as a growth spurt ([8](#)), the most vulnerable phase to the progression of scoliotic curvature, reaching 20 to 90% depending on the Cobb angle measurement, reliable radiographic parameters and with great clinical applicability for monitoring the progression of scoliosis ([9](#)).

To measure the Cobb angle, the X-ray examination, considered the gold standard, is done using two-dimensional or three-dimensional radiography (X-ray / 2D or 3D) taken for the sagittal and anteroposterior profiles. Cobb's method, the most widespread in clinical and scientific practice ([9](#)), measures the angle of the projection of a line tangent at the top of the vertebra, indicating the beginning of the spine's curvature, and another line tangent at the base of the vertebra, which indicates the end of the spine's curvature. Perpendicular lines are added to each line and the acute angle between them, called the Cobb angle, is measured. According to Goldberg et al., ([10](#)) Wills et al., ([11](#)) and Ricart et al., ([12](#)) the Cobb method is accurate and precise for radiographic measurements in traditional or digital printed form as well as for digital only measurements made through computer software. Despite being an effective and highly valid method, X-ray examination remains risky for patients with scoliosis: According to some authors, scoliotic patients monitored from childhood to adolescence underwent an average of 25 X-ray imaging exams to monitor the Cobb angle, corresponding to an average of 10.8 cGy ionizing radiation, increasing the risk of breast cancer and infertility in affected adolescents([13](#)).

Three-dimensional (3D) exams, called EOS, have been included in current clinical and scientific practice to achieve better precision when assessing scoliotic curvatures (thoracic and lumbar), using an innovative ultra-sensitive X-ray imaging system that allows rapid (20 seconds) 3D exams ([14,15](#)). This method is advantageous because it reduces radiation dosages by up to 85% compared to traditional or digital radiography, both of which use standard two-dimensional (2D) X-ray technology ([15,16](#)). Despite this innovative method's considerable precision when measuring thoracic and lumbar scoliotic curvatures, the EOS system has high financial costs for patients, making it difficult for patients in the a single-payer healthcare system to access this exam, so scoliosis monitoring has largely remained in the form of traditional X-ray examinations ([14,16](#)).

Given this context, great efforts have been made by researchers and clinicians to uncover possible resources to indirectly measure the sagittal parameters of the spine as a way of monitoring scoliotic curvatures that would be

predisposed to the lowest radioactive exposure of X-rays but maintain the precision and accuracy of scoliotic measurements of thoracic and lumbar curvatures in the prognosis of curvature progression. According to Tabard-Fougère et al., (17) accurate non-radioactive clinical tools for measuring scoliotic curvatures are needed to monitor the progression of this deformity during an adolescent's growth phase.

The literature presents several radiation-free instruments to assess and monitor the progression of scoliotic curvature angles in the AIS. The instruments presented in the literature are the flexicurve (18), the manual inclinometer (19) or inclinometer assisted by smartphone (19), the 3D ultrasound (20), the Zebris column system (21), rastereography (17,22), Scolioscan (23), and the electrogoniometer (24). Of all the instruments described in the literature, the inclinometer stands out in clinical practice, given its applicability-both manual (17) and digital (19)-and because it is a simple, fast system with a low cost which has received wide attention from many authors and doctors for measuring and monitoring the progression of scoliotic curvature in patients with AIS.

The applicability of the inclinometer is based on studies that refer to excellent reliability ( $ICC > 0.90$ ) when compared to the X-ray image exam (17,19,22). However, the reliability and validity of the inclinometer at different stages of growth were not understood until recently, which underscores the significant clinical relevance of this study, since radiation doses from X-ray exams as part of the monitoring of scoliotic curvature in the growth phase is a major issue and greatly challenges the health and well-being of adolescents affected by idiopathic scoliosis. Thus, the aim of this study was to assess the reliability of the inclinometer and compare it to the gold standard of X-ray examination of the sagittal parameters of the spine in the early and late growth stages of adolescents with idiopathic scoliosis. We hypothesized that in the initial phase of growth, the inclinometer would present excellent reliability and validity in relation to the radiographic examination when compared to the late phase of growth.

## MATERIALS AND METHODS

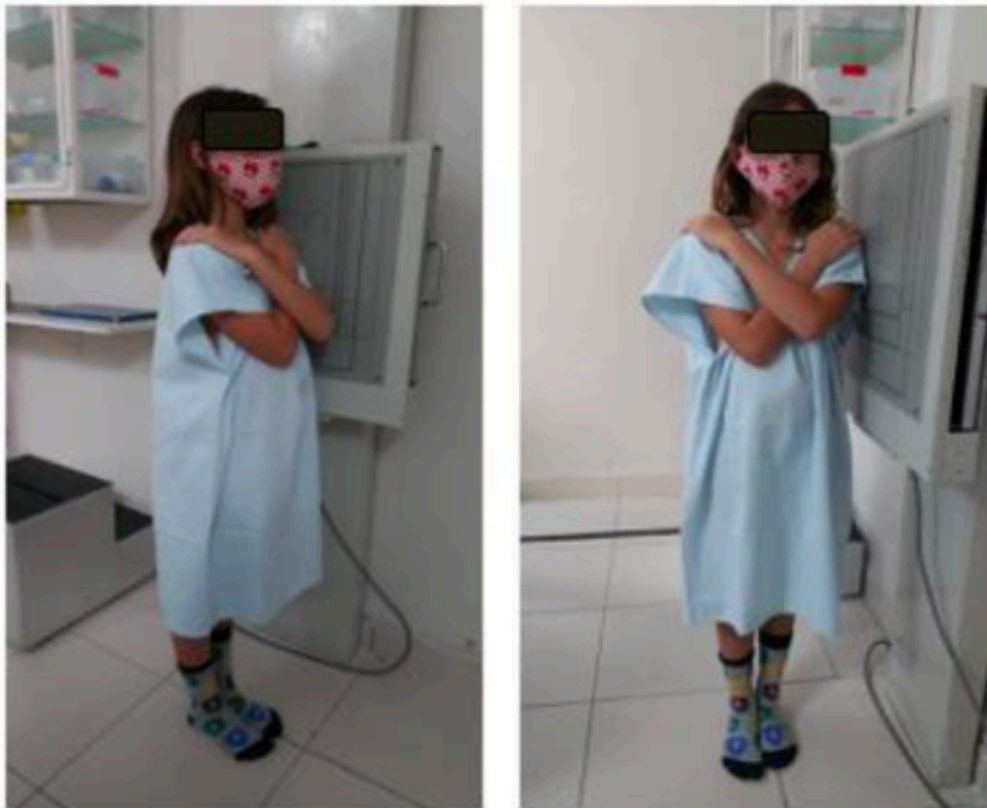### Study Design and Participants

This study had a cross-sectional design. The sample consisted of 39 adolescents with AIS seen at Clinica Escoliose Brasil, in the city of Campinas, São Paulo/SP. Adolescents were divided into two groups according to Risser sign: an initial growth phase (Group 1, 10-13 years,  $n = 16$ , Risser 1 or 2) and a late growth phase (Group 2, 14-18 years,  $n = 23$ , Risser 3 or 4). All adolescents or their respective legal guardians signed the Free and Informed Consent Term, previously approved by the Research Ethics Committee of the University of Santo Amaro, on the number: 2.729.155.

The following were the inclusion criteria: participants had to be between 10 and 18 years of age, diagnosed with idiopathic scoliosis with a Cobb angle between 20 and 40° according to a two-dimensional X-ray exam, considered the gold standard for scoliosis detection, as measured by a responsible doctor. The exclusion criteria were as follows: a body mass index (BMI)  $\geq 29$ , other neurological, rheumatic, or orthopedic pathologies of the spine or lower limbs, presence of fractures less than six months old, respiratory or cardiac disorders, symptomatic musculoskeletal diseases in lower limbs, symptomatic diseases of the central and peripheral nervous system, diabetes mellitus, corrective surgery of the curvature of the spine, rigid deformities in the feet, infiltrations in the feet and ankles in the last three months, inability to stand and walk more than 100 m, mental disability, and the presence of tattoos or scars on the back (17).

### Examination of X-ray Image and Evaluation of Inclinometer

Each adolescent was recruited for two evaluations: first, biplane radiography and second, inclinometer evaluation. It is worth mentioning that the radiographic evaluations were performed on different days, considering the time taken by the patient to schedule the same. When performing a biplane, a two-dimensional radiographic image, all adolescents underwent the X-ray image in the sagittal profile of the spine as part of the medical request to monitor and confirm the diagnosis of idiopathic scoliosis (Figure 1)(17). To undergo the X-ray examination, adolescents remained in an orthostatic posture in a standing position supporting their own body weight. The patients' feet remained in the same alignment in the frontal plane, with 7.5 cm between them. To reduce artifacts due to the projection of the humerus overlapping the spine, side imaging was completed with adolescents crossing their arms, fingers resting on the collarbones. The X-ray images were digitized and analyzed by physical therapist 1. After four weeks, the images were reevaluated by the same physical therapist and by a second physical therapist.

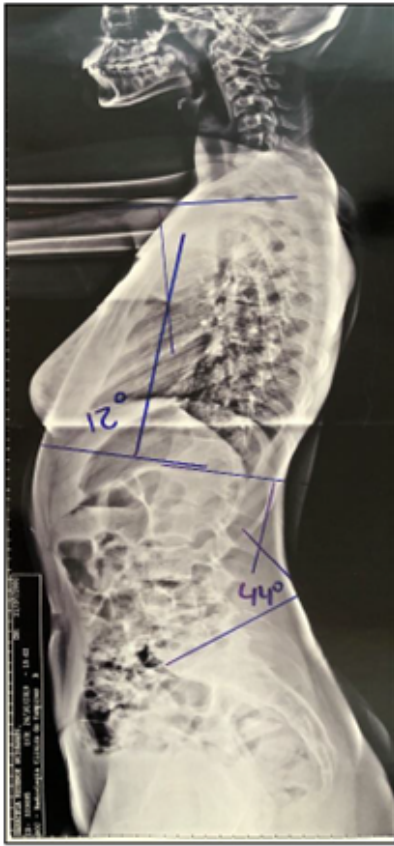

**Figure 1** Representation of the performance of the frontal and sagittal profile of the X-ray image exam.

Immediately following the X-ray examination, the adolescent was referred to a physiotherapy clinic to assess sagittal, thoracic, and lumbar curvatures using the inclinometer (Tozz® magnetic base). In this evaluation, the adolescent was positioned in a standing orthostatic posture with body weight support, feet spread 7.5 cm and separated by ethyl acetate vinyl-EVA. The adolescents remained standing, with the physiotherapists measuring the sagittal angles of thoracic kyphosis and lumbar lordosis when positioned to the side of the spine (sagittal plane). When measuring, both physiotherapists maintained the base of the inclinometer on the two spinous processes directed directly at the surface of the back, and the difference between the two measured values was the calculated angle. The standardization of the base of the two inclinometers was 2.5 cm for all evaluated adolescents.

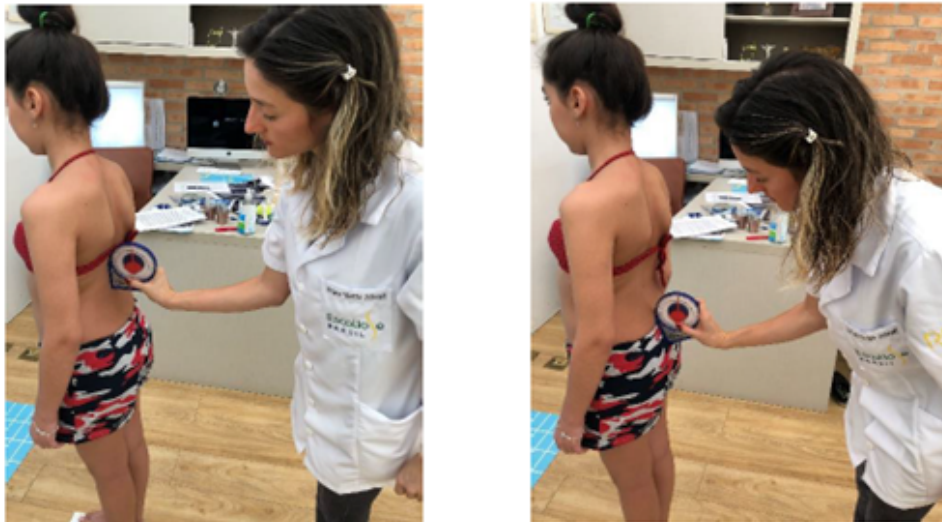### **Evaluation Parameters of Sagittal Angles: Thoracic Kyphosis and Lumbar Lordosis**

To evaluate the digital X-ray image, the thoracic kyphosis (CT) angle was measured between the line tangent to the cranial ends of the fourth thoracic vertebra (T4) and the caudal end of the 12th thoracic vertebra (T12), and the angle of the lumbar lordosis (LL) was measured between the tangent at the cranial end of L1 and sacral (S1), called L1-S1 ([Figure 2](#)).



**Figure 2** Representation of the sagittal angles of thoracic kyphosis and lumbar lordosis in the X-ray imaging of adolescents with idiopathic scoliosis.

Using the inclinometer, the angle of thoracic kyphosis (CT) was measured by placing the base of the instrument on the spinous processes of T1-T2 and T12-L1, previously located by manual palpation. The angle of lumbar lordosis (LL) was measured by placing the base of the inclinometer over T12-L1 and L5-S1. In total, measurements were repeated three times by the same physiotherapist and the average of these measures was used for data analysis ([Figure 3](#)).



**Figure 3** Representation of the sagittal angles of thoracic kyphosis and lumbar lordosis on the inclinometer of adolescents with idiopathic scoliosis.

## Data Reliability Analysis

To verify the degree of reliability of the intra-examiner analysis between the different instruments X-ray and inclinometer, a single examiner (physiotherapist 1) used an inclinometer to measure the sagittal angles with an interval of one week between the first and second X-ray assessments to ensure that there would be no memorization of the angles. To assess the inter-examiner reliability of the sagittal angles, two examiners (physiotherapists 1 and 2) evaluated the sagittal angles using both instruments-X-ray imaging and inclinometer on the same day but in different environments to ensure that no information regarding data analysis could be exchanged, which would have interfered with the final result of the analysis ([17](#), [19](#)).

## Statistical Analysis

The normality of the data was verified using the Shapiro-Wilk test, and after confirming the non-normality of the data, nonparametric tests were performed. The Mann-Whitney test was used to compare the anthropometric variables of Groups 1 and 2 (i.e., the early and late growth stage groups). The Wilcoxon test was used to separately compare the sagittal parameters of the angles of thoracic kyphosis and lumbar lordosis according to each physiotherapist's measurements using each instrument (inclinometer and X-ray) and for each group. The same test was applied to compare the percentage differences between X-ray examination and inclinometer evaluation (percentage variation delta) for each evaluator. The Mann-Whitney test was used to compare the measurements by physiotherapists 1 and 2 of the sagittal angles for each instrument and group. These measurements were performed according to the sagittal parameters of the angles of thoracic kyphosis and lumbar lordosis for adolescents with AIS in the early and late growth phases.

To assess the intra- and inter-examiner reliability of inclinometer measurements in adolescents with AIS in the early and late stages of growth, the intraclass correlation coefficient (ICC) was used. To calculate the ICC equation type (1, 1) for the intra-examiner analysis, measurements were made one week apart by the same examiner, and for the ICC type equation (3, 3) for intra-examiner reliability, measurements were performed by physiotherapist 1 and physiotherapist 2 ([24](#)). The ICC was considered excellent if greater than 0.75, moderate between 0.74 and 0.40, and poor if less than 0.39. To calculate the percentage delta differences, the following formula was applied:  $\Delta \% = X\text{-ray angle} - \text{inclinometer angle} \times 100$

X-ray angle

To assess the construct validity between inclinometer and radiography, Spearman's correlation coefficients were calculated. The percentage differences between inclinometer and radiograph measurements for the thoracic kyphosis and lumbar lordosis angles for Groups 1 and 2 were compared, and participants with differences greater than 5 ° were compared. For all analyses,  $p < 0.05$  was considered significant ([24](#)).

## Results

Adolescents with AIS in various stages of growth showed similar anthropometric characteristics. The differences between groups related to age and Risser sign, which demonstrate differences in the maturity of musculoskeletal systems, as observed in [Table 1](#).

**Table 1:** Adolescents with idiopathic scoliosis in early and late growth stages according to body mass, height, body mass index, Cobb angle, and Risser sign.

Variables	Initial growth phase (Group 1) mean (SD)	Late growth stage (Group 2) mean (SD)	p
Age (years)	12.3 (1.0)	15.0 (1.7)	0.001*
Body Mass (kg)	49.4 (8.0)	50.6 (11.0)	0.463
Height (m)	1.60 (0.1)	1.5 (0.2)	0.674
Body Mass Index-BMI (kg /m <sup>2</sup> )	20.3 (3.3)	24.1 (4.9)	0.124
Thoracic Cobb Angle (degrees)	31.8 (13.3)	33.0 (8.4)	0.369
Lumbar Cobb Angle (degrees)	32.4 (8.8)	32.7 (7.8)	0.412
Risser sign (score)	and 2 (1.6)	3 and 4 (3.1)	0.019*

\* Mann-Whitney test, considering significant differences  $p < 0.05$ .

[Table 2](#) shows that the sagittal angle of lumbar lordosis was found to be significant between the X-ray and inclinometer measurements, considering the same evaluator, both for the early and late growth stages. The angle of thoracic kyphosis showed no significant difference between the inclinometer and X-ray measurements when considering evaluations by a single examiner. Based on these findings, it can be inferred that the sagittal parameter of the spine of the lumbar lordosis angle is not effective; therefore, caution should be exercised when using the inclinometer to measure the lumbar lordosis angle given the significant differences between its measurements and the measurements of X-ray imaging for both the early and late growth phases.

**Table 2:** Sagittal parameters of thoracic kyphosis and lumbar lordosis measured by X-ray and inclinometer for each evaluator in adolescents with idiopathic scoliosis in early and late stages of growth.

Group 1: Early growth phase (10–13 years)						
Sagittal Angles	Examiner 1			Examiner 2		
	X-ray	Inclinometer	Delta (variation)	X-ray	Inclinometer	Delta (variation)
<b>Thoracic kyphosis</b>						
Mean (SD)	34.1 (11.3)	31.1 (10.0)	3.0	33.0 (8.4)	32.6 (9.6)	0.4
Minimum / maximum	18 / 58	20 / 55		18 / 60	18 / 58	
<b>p</b>	p = 0.917			p = 0.897		
<b>Delta (Ex.1 - Ex.2)</b>	p = 0.958					
<b>Lumbar lordosis</b>						
Mean (SD)	33.6 (8.4)	44.3 (14.2)	11.0	35.0 (7.7)	40.3 (10.2)	5.3
Minimum / maximum	22 / 47	19 / 58		23 / 47	23 / 58	
<b>p</b>	p = 0.005* (Inclinometer > X-ray)			p = 0.013* (Inclinometer > X-ray)		
<b>Delta (Ex.1 - Ex.2)</b>	p = 0.043*					
Group 2: Late growth phase (14–18 years)						
Sagittal Angles	Examiner 1			Examiner 2		
	X-ray	Inclinometer	Delta (variation)	X-ray	Inclinometer	Delta (variation)
<b>Thoracic kyphosis</b>						
Mean (SD)	33.0 (8.3)	32.7 (9.6)	0.3	34.5 (8.2)	35.8 (8.5)	1.3
Minimum maximum	18 / 52	18 / 56		18 / 60	18 / 59	
<b>p</b>	p = 0.732			p = 0.162		
<b>Delta (Ex.1 - Ex.2)</b>	p = 0.445					
<b>Lumbar lordosis</b>						
Mean (SD)	34.9 (5.5)	42.8 (6.8)	7.9	35.0 (7.0)	41.1 (7.8)	6.1
Minimum maximum	28 / 52	30 / 60		22 / 50	24 / 56	
<b>p</b>	< 0.001* (Inclinometer > X-ray)			0.001* (Inclinometer > X-ray)		
<b>Delta (Ex.1 - Ex.2)</b>	p = 0.684					

Wilcoxon test, considering significant differences  $p < 0.05$ .

[Table 3](#) shows that for X-ray examinations, there was no significant difference between the physiotherapists' measurements of the sagittal angles of thoracic kyphosis and lumbar lordosis for the early and late phases of growth. It was also observed that the inclinometer effectively compared physiotherapists 1 and 2 when measuring the angle of thoracic kyphosis for early and late phases of growth. The sagittal parameter of the lumbar lordosis angle for physiotherapists 1 and 2 was significantly different for each phase of growth, which indicates that it has little clinical applicability for evaluating adolescents with AIS.



**Table 3:** Inter-evaluator sagittal parameters of thoracic kyphosis and lumbar lordosis according to X-ray image examination of adolescents with idiopathic scoliosis in different stages of growth.

X-ray		Group 1: Early growth phase (10–13 years)		
Sagittal Angles		Examiner 1	Examiner 2	p*
Thoracic kyphosis (mean / SD)		34.1 (11.3)	33.0 (8.4)	0.796
Minimum / maximum		18 / 58	18 / 60	
Lumbar lordosis (mean / SD)		33.6 (8.4)	35.0 (7.7)	0.637
Minimum / maximum		22 / 47	23 / 47	
X-ray		Group 2: Late growth stage (14–18 years)		
Sagittal Angles		Examiner 1	Examiner 2	p*
Thoracic kyphosis (mean / SD)		33.0 (8.3)	34.5 (8.2)	0.233
Minimum / maximum		18 / 52	18 / 60	
Lumbar lordosis (mean / SD)		34.9 (5.5)	35.0 (7.0)	0.975
Minimum / maximum		28 / 52	22 / 50	
Inclinometer		Group 1: Early growth phase (10–13 years)		
Sagittal Angles		Examiner 1	Examiner 2	p*
Thoracic kyphosis (mean / SD)		31.1 (10.0)	32.6 (9.6)	0.798
Minimum / maximum		20 / 55	18 / 58	
Lumbar lordosis (mean / SD)		44.3 (14.2)	40.3 (10.2)	0.162
Minimum / maximum		19 / 58	23 / 58	
Inclinometer		Group 2: Late growth stage (14–18 years)		
Sagittal Angles		Examiner 1	Examiner 2	p*
Thoracic kyphosis (mean / SD)		32.7 (9.6)	35.8 (8.5)	0.006*
Minimum / maximum		18 / 56	18 / 59	
Lumbar lordosis (mean / SD)		42.8 (6.8)	41.1 (7.8)	0.001*
Minimum / maximum		30 / 60	24 / 56	

Mann-Whitney test, considering significant differences  $p < 0.05$ .

[Tables 4](#) and [5](#) display the early and late growth phases with moderate intra-examiner reliability (ICC = 0.62; ICC = 65, respectively) and inter-examiner reliability (ICC = 0.64; ICC = 0.48, respectively) for the sagittal angle of lumbar lordosis when measured using an inclinometer. Only the sagittal parameter of the thoracic kyphosis angle showed excellent intra-examiner reliability (ICC = 0.88 for Group 1 and ICC = 0.90 for Group 2) and inter-examiner reliability (ICC = 0.86 for Group 1 and ICC = 0.85 for Group 2) when measured using an inclinometer. This indicates a moderate agreement of the sagittal angle of lumbar lordosis when measured using an inclinometer for the early and late growth phases when monitoring the scoliotic curvature of adolescents, considering the excellent reliability of the sagittal parameters of thoracic kyphosis and lumbar lordosis by X-ray.

**Table 4:** Intra- and inter-examiner reliability according to the intraclass correlation coefficient (ICC) of the sagittal angles of thoracic kyphosis and lumbar lordosis measured using both an inclinometer and radiography in adolescents with idiopathic scoliosis in the early phase of growth. \* Intra-Class Correlation Coefficient (ICC), considering significant differences  $p < 0.05$ .

Sagittal Parameters	Examiner 1 Mean (SD)	Examiner 2 Mean (SD)	ICC	p	Examiner 1 Mean (SD)	ICC	p
<b>Thoracic Kyphosis</b>							
Inclinometer (°)	31.1 (10.0)	32.6 (9.6)	0.86	0.557	32.2 (9.3)	0.88	0.563
Radiograph (°)	34.1 (11.3)	33.0 (8.4)	0.93	0.721	33.6 (8.5)	0.92	0.681
<b>Lumbar Lordosis</b>							
Inclinometer (°)	44.3 (14.2)	40.3 (10.2)	0.64	0.045*	48.6 (8.5)	0.62	0.038*
Radiograph (°)	33.6 (8.4)	35.0 (7.7)	0.91	0.492	34.5 (8.2)	0.96	0.675

**Table 5:** Intra- and inter-examiner reliability according to the intraclass correlation coefficient (ICC) of the sagittal angles of thoracic kyphosis and lumbar lordosis measured using both an inclinometer and radiography in adolescents with idiopathic scoliosis in the late phase of growth. \* Intra-Class Correlation Coefficient (ICC), considering significant differences  $p < 0.05$ .

Group 2 (14-18 years)	Inter-Examiner (same day)				Intra-Examiner (a week later)			
	Sagittal Parameters	Examiner 1 Mean (SD)	Examiner 2 Mean (SD)	ICC	p	Examiner 1 Mean (SD)	ICC	P
<b>Thoracic Kyphosis</b>								
Inclinometer (°)	32.7 (9.6)	35.8 (8.5)	0.85	0.130	32.9 (9.1)	0.90	0.652	
Radiograph (°)	33.0 (8.3)	34.5 (8.2)	0.95	0.579	33.2 (8.1)	0.96	0.846	
<b>Lumbar Lordosis</b>								
Inclinometer (°)	42.8 (6.8)	41.1 (7.8)	0.48	0.009*	38.7 (8.5)	0.65	0.040*	
Radiograph (°)	34.9 (5.5)	35.0 (7.0)	0.88	0.744	34.2 (5.3)	0.92	0.942	

**Table 6** shows the weak correlation between the measurements of the sagittal angle of lumbar lordosis using an inclinometer and using X-ray imaging for both the early and late growth phases, demonstrating inefficient validity to use thoracic kyphosis and lumbar lordosis to monitor the sagittal parameter of the spine in adolescents with AIS.

**Table 6:** Correlation between inclinometer and X-ray measurements of sagittal parameters for thoracic kyphosis and lumbar lordosis during early and late stages of growth of adolescents with idiopathic scoliosis.

Instruments: Group 1	Thoracic Kyphosis (°)	Lumbar Lordosis (°)
<b>Gold Standard (radiography)</b>	T4-T12	L1-S1
Mean (SD)	34.1 (11.3)	33.6 (8.4)
<b>Inclinometer (initial growth phase)</b>		
Mean (SD)	31.1 (10.0)	44.3 (14.2)
N (%) patients with differences > 5°	5/16	10/16
Correlation (r)	0.84	0.38
p	0.308	0.001*
Instruments: Group 2	Thoracic Kyphosis (°)	Lumbar Lordosis (°)
<b>Gold Standard (radiography)</b>	T4-T12	L1-S1
Mean (median)	33.0 (8.3)	34.9 (5.5)
<b>Inclinometer (late stage of growth)</b>		
Mean (median)	32.7 (9.6)	41.1 (7.8)
N (%) patients with differences > 5°	8/21	15/21
Correlation (r)	0.75	0.49
p	0.517	0.024*

\* Spearman's correlation test, considering significant differences  $p < 0.05$ .

## DISCUSSION

This study evaluates the inter- and intra-examiner agreement (reliability) of the inclinometer, a radiation-free instrument, and its relationship with the gold standard of the X-ray exam on the sagittal parameters of the spine in the early and late growth phase of AIS. The main results showed that the sagittal angle of lumbar lordosis was different between the X-ray and inclinometer measurements taken by the same physiotherapist for both the early and late growth stages. When used by different physiotherapists, the inclinometer yielded differing measurements for the lumbar lordosis angle for early and late phases of growth; this demonstrates that the inclinometer has little clinical applicability for monitoring the scoliotic curvature of the lumbar in AIS. Another important point was the inclinometer's moderate intra-examiner and inter-examiner reliability when measuring the sagittal angle of lumbar lordosis; the thoracic kyphosis angle demonstrated excellent intra-examiner and inter-examiner reliability for the different stages of growth. In addition, the sagittal angle of lumbar lordosis measured using an inclinometer was weakly correlated to the gold standard of X-ray examination in the early and late stages of growth. This demonstrates that it is an inefficient method for monitoring the sagittal parameter of the spine in adolescents with AIS. The angle of thoracic kyphosis was shown to be highly correlated with the X-ray examination. The sagittal parameter of thoracic kyphosis for adolescents with AIS who were in different growth phases did not vary when measured using X-ray imaging and using an inclinometer, but measurements of the sagittal parameter of lumbar lordosis were affected by the different stages of growth. One study has considered variations in measurements of the angle of thoracic kyphosis (T4-T12 and T5-T12), and the sagittal parameter has been revealed as crucial for the clinical practice of monitoring the progression of scoliotic curvatures by means of X-ray examination (24). Other studies have revealed that the sagittal parameters of the spine (thoracic kyphosis and lumbar lordosis) of an adolescent with scoliosis should be monitored using radiation-free instruments, including the manual inclinometer (17) and the digital inclinometer (19), that demonstrate good reproducibility for sagittal angles measurements. The differential of this study was to consider the early and late phases of growth and to show that measurements of the sagittal parameter of lumbar lordosis using an inclinometer would differ significantly between examiners. Thus, it can be inferred that health professionals should be very cautious when assessing the clinical applicability of the inclinometer to monitor the scoliotic curvature of the lumbar of adolescents with AIS. It is important to consider the different growth phases when using a radiation-free instrument, such as the inclinometer, because an instrument is needed that can identify scoliotic curvature while the bone tissue is maturing while also maintaining the precision and accuracy of sagittal measurements of the spine (22,27). This study has shown that the inclinometer has moderate intra-examiner and inter-examiner reliability for the sagittal angle of lumbar lordosis; furthermore, the thoracic kyphosis angle showed excellent intra-examiner and inter-examiner reliability in the early and late stages of growth. These results corroborate the study by Tabard-Fougère et al., (17) who observed that the angles of thoracic kyphosis and lumbar lordosis measured using an inclinometer are reliable for adolescents with AIS but have a weak correlation with the angle of lumbar lordosis when compared with X-ray imaging. The literature has emphasized the good correlation of the angle of thoracic kyphosis using various radiation-free instruments-namely, the flexicurve(18), the 3D ultrasound (20), the ZEBRIS system(21), rastereography (17,22), Scolioscan (23), and the electrogoniometer (28) - to evaluate adolescents with scoliosis. Among all these instruments, the inclinometer has stood out both clinically and scientifically, given its easy applicability and low cost, which has proven to be reliable and valid when measuring the angle of thoracic kyphosis but which has a weak correlation with the angle of lumbar lordosis (17,19,22), as observed in the present study. However, other studies that used surface topography have shown a good correlation between the angle of lumbar lordosis and the X-ray measurement in adolescents with idiopathic scoliosis (30,31). Differences in the angle of lumbar lordosis and its weak correlation when compared to the gold standard of X-ray examination might be due to variations in the anatomical positioning of the inclinometer for the repeated intra-examiner evaluations and between the evaluators (inter-examiner); this supports the low validity of this instrument when used for adolescents with idiopathic scoliosis. These discrepancies might also be due to the various factors that can affect the curvature of lumbar lordosis, including tension in the ligaments, tension between the paravertebral, hip, and abdominal muscles, and the inclination of the pelvis both in the orthostatic position and during the pubertal growth spurt, which contribute to the misalignment of the lumbosacral vertebrae in the sagittal plane, especially in relation to spinal deformities such as scoliosis (32). The inclinometer has had great applicability in clinical practice and has received wide scientific and clinical attention from health professionals for measuring and monitoring the progression of scoliotic curvature in adolescents with idiopathic scoliosis. Its applicability has been guided by studies that refer to excellent reliability ( $ICC > 0.90$ ) when compared against the X-ray image exam (17,19,22,23). This study is clinically relevant because it demonstrates the reliability and validity of the inclinometer at different stages of

growth for the angle of thoracic kyphosis although not for the angle of lumbar lordosis compared to the gold standard of the X-ray. Reducing radiation exposure when monitoring scoliotic curvature in adolescents is a major issue, as radiation challenges the health and well-being of adolescents with scoliosis. This study is limited because the inclinometer's performance was not compared against X-ray exams using the EOS system, which reproduces micro-doses of radiation two to three times smaller than the traditional X-ray. According to the literature, the EOS system has a lower radioactive dosage but is very expensive and is generally not available to the public health system; thus, it is difficult for affected adolescents to benefit from this system.<sup>26, 34</sup> Therefore, future studies concerning these measurement tools should better understand the sagittal parameters of the spine at different stages of growth in adolescents with idiopathic scoliosis.

## CONCLUSION

The early and late phases of growth showed excellent inter- and intra-examiner agreement (reliability) regarding measurements by the inclinometer, a radiation-free instrument, of the sagittal parameter of thoracic kyphosis as well as moderate reliability regarding the angle of lumbar lordosis. Another important finding was the weak correlation of the inclinometer in comparison to with the X-ray's measurements of the angle of lumbar lordosis for both the early and late growth stages, showing the inclinometer to be an inefficient instrument for monitoring the scoliotic curvature of the lumbar spine of adolescents with idiopathic scoliosis.

## Acknowledgements

The authors acknowledge for help and support of the all the participants and Spine Group of the Institute of Medical Assistance to the State Public Hospital Servant and clinical center of the spine, in the state of Sao Paulo/SP, Brazil, during study.

## Competing interests

The author(s) declared no potential conflicts of interest with respect to the research and/or publication.

## Funding

This study has received funding from the National Council for Scientific and Technological Development (CNPq), Ministry of Science, Technology, Innovations and Communications of the Brazil under grant number: 458700/2014, São Paulo/SP. The funding bodies had no role in the design of the study, the data collection, data analysis, interpretation of the data or writing the manuscript.

ORCID Ana Paula Ribeiro <https://orcid.org/0000-0002-1061-3789>

## Consent for publication

Not Applicable

Availability of data and materials

The datasets used and/or analysed during the current study are available from the corresponding author (apribeiro@alumni.usp.br) on reasonable request.

## Authors' contributions

All authors were involved in drafting the article or revising it critically for important intellectual content, and all authors approved the final version to be published. Study conception, writing and design: AVS and APR. Acquisition of data and Statistics: AVS, RMA, NFN and APR. Analysis and interpretation of data: AVS, NFN and APR.

## REFERENCES

1. Grivas, T. B., Vasiliadis, E., Mouzakis, V., Mihas, C., & Koufopoulos, G. (2006). Association between adolescent idiopathic scoliosis prevalence and age at menarche in different geographic latitudes. *Scoliosis*, 1, 9.

<https://doi.org/10.1186/1748-7161-1-9>. [ [Links](#) ]

2. Smania, N., Picelli, A., Romano, M., & Negrini, S. (2008). Neurophysiological basis of rehabilitation of adolescent idiopathic scoliosis. *Disability and rehabilitation*, 30(10), 763-771.

<https://doi.org/10.1080/17483100801921311>. [ [Links](#) ]

3. Dickson R. A. (1983). Scoliosis in the community. *British medical journal (Clinical research ed.)*, 286(6365), 615-618. <https://doi.org/10.1136/bmj.286.6365.615>. [ [Links](#) ]

4. Soucacos, P. N., Soucacos, P. K., Zacharis, K. C., Beris, A. E., & Xenakis, T. A. (1997). School-screening for scoliosis. A prospective epidemiological study in northwestern and central Greece. *The Journal of bone and joint surgery. American volume*, 79(10), 1498-1503. <https://doi.org/10.2106/00004623-199710000-00006>. [ [Links](#) ]

5. Penha, P. J., Ramos, N., de Carvalho, B., Andrade, R. M., Schmitt, A., & João, S. (2018). Prevalence of Adolescent Idiopathic Scoliosis in the State of São Paulo, Brazil. *Spine*, 43(24), 1710-1718.

<https://doi.org/10.1097/BRS.0000000000002725>. [ [Links](#) ]

6. Lee, C. F., Fong, D. Y., Cheung, K. M., Cheng, J. C., Ng, B. K., Lam, T. P., Mak, K. H., Yip, P. S., & Luk, K. D. (2010). Referral criteria for school scoliosis screening: assessment and recommendations based on a large longitudinally followed cohort. *Spine*, 35(25), E1492-E1498. <https://doi.org/10.1097/BRS.0b013e3181ecf3fe>.

[ [Links](#) ]

7. Freidel, K., Petermann, F., Reichel, D., Steiner, A., Warschburger, P., & Weiss, H. R. (2002). Quality of life in women with idiopathic scoliosis. *Spine*, 27(4), E87-E91. <https://doi.org/10.1097/00007632-200202150-00013>.

[ [Links](#) ]

8. Rose, P. S., & Lenke, L. G. (2007). Classification of operative adolescent idiopathic scoliosis: treatment guidelines. *The Orthopedic clinics of North America*, 38(4), 521-vi. <https://doi.org/10.1016/j.ocl.2007.06.001>.

[ [Links](#) ]

9. Wu, W., Liang, J., Du, Y., Tan, X., Xiang, X., Wang, W., Ru, N., & Le, J. (2014). Reliability and reproducibility analysis of the Cobb angle and assessing sagittal plane by computer-assisted and manual measurement tools. *BMC musculoskeletal disorders*, 15, 33. <https://doi.org/10.1186/1471-2474-15-33>. [ [Links](#) ]

10. Goldberg, C. J., Moore, D. P., Fogarty, E. E., & Dowling, F. E. (2006). Handedness and spinal deformity.

*Studies in health technology and informatics*, 123, 442-448. [ [Links](#) ]

11. Wills, B. P., Auerbach, J. D., Zhu, X., Caird, M. S., Horn, B. D., Flynn, J. M., Drummond, D. S., Dormans, J. P., & Ecker, M. L. (2007). Comparison of Cobb angle measurement of scoliosis radiographs with preselected end vertebrae: traditional versus digital acquisition. *Spine*, 32(1), 98-105.

<https://doi.org/10.1097/01.brs.0000251086.84420.d1>. [ [Links](#) ]

12. Ricart, P. A., Andres, T. M., Apazidis, A., Errico, T. J., & Trobisch, P. D. (2011). Validity of Cobb angle measurements using digitally photographed radiographs. *The spine journal: official journal of the North American Spine Society*, 11(10), 942-946. <https://doi.org/10.1016/j.spinee.2011.09.003>. [ [Links](#) ]

13. Pesenti, S., Prost, S., Blondel, B., Pomeroy, V., Severyns, M., Roscigni, L., Authier, G., Viehweger, E., & Jouve, J. L. (2019). Correlations linking static quantitative gait analysis parameters to radiographic parameters in adolescent idiopathic scoliosis. *Orthopaedics & traumatology, surgery & research: OTSR*, 105(3), 541-545.

<https://doi.org/10.1016/j.otsr.2018.09.024>. [ [Links](#) ]

14. Hui, S. C., Pialasse, J. P., Wong, J. Y., Lam, T. P., Ng, B. K., Cheng, J. C., & Chu, W. C. (2016). Radiation dose of digital radiography (DR) versus micro-dose x-ray (EOS) on patients with adolescent idiopathic scoliosis: 2016 SOSORT- IRSSD "John Sevastic Award" Winner in Imaging Research. *Scoliosis and spinal disorders*, 11, 46.

<https://doi.org/10.1186/s13013-016-0106-7>. [ [Links](#) ]

15. Lau, L., Hung, A., Chau, W. W., Hu, Z., Kumar, A., Lam, T. P., Chu, W., & Cheng, J. (2019). Sequential spine-hand radiography for assessing skeletal maturity with low radiation EOS imaging system for bracing treatment recommendation in adolescent idiopathic scoliosis: a feasibility and validity study. *Journal of children's orthopaedics*, 13(4), 385-392. <https://doi.org/10.1302/1863-2548.13.190007>. [ [Links](#) ]

16. Goussard, P., Gie, R., Andronikou, S., & Fourie, P. R. (2013). A correctable cause of lung collapse in an adolescent with severe scoliosis causing compression of the bronchial tree. *BMJ case reports*, 2013, bcr2013202017. <https://doi.org/10.1136/bcr-2013-202017>. [ [Links](#) ]

17. Tabard-Fougère, A., Bonnefoy-Mazure, A., Dhouib, A., Valaikaite, R., Armand, S., & Dayer, R. (2019). Radiation-free measurement tools to evaluate sagittal parameters in AIS patients: a reliability and validity study. *European spine journal : official publication of the European Spine Society, the European Spinal Deformity Society, and the European Section of the Cervical Spine Research Society*, 28(3), 536-543. <https://doi.org/10.1007/s00586-018-05875-1>. [ [Links](#) ]
18. Greendale, G. A., Nili, N. S., Huang, M. H., Seeger, L., & Karlamangla, A. S. (2011). The reliability and validity of three non-radiological measures of thoracic kyphosis and their relations to the standing radiological Cobb angle. *Osteoporosis international: a journal established as result of cooperation between the European Foundation for Osteoporosis and the National Osteoporosis Foundation of the USA*, 22(6), 1897-1905. <https://doi.org/10.1007/s00198-010-1422-z>. [ [Links](#) ]
19. Qiao, J., Liu, Z., Xu, L., Wu, T., Zheng, X., Zhu, Z., Zhu, F., Qian, B., & Qiu, Y. (2012). Reliability analysis of a smartphone-aided measurement method for the Cobb angle of scoliosis. *Journal of spinal disorders & techniques*, 25(4), E88-E92. [ [Links](#) ]
20. Vrtovec, T., Janssen, M. M., Likar, B., Castelein, R. M., Viergever, M. A., & Pernuš, F. (2012). A review of methods for evaluating the quantitative parameters of sagittal pelvic alignment. *The spine journal: official journal of the North American Spine Society*, 12(5), 433-446. <https://doi.org/10.1016/j.spinee.2012.02.013>. [ [Links](#) ]
21. Takács, M., Orlovits, Z., Jáger, B., & Kiss, R. M. (2018). Comparison of spinal curvature parameters as determined by the ZEBRIS spine examination method and the Cobb method in children with scoliosis. *PLoS one*, 13(7), e0200245. <https://doi.org/10.1371/journal.pone.0200245>. [ [Links](#) ]
22. Tabard-Fougère, A., Bonnefoy-Mazure, A., Hanquinet, S., Lascombes, P., Armand, S., & Dayer, R. (2017). Validity and Reliability of Spine Rasterstereography in Patients With Adolescent Idiopathic Scoliosis. *Spine*, 42(2), 98-105. <https://doi.org/10.1097/BRS.0000000000001679>. [ [Links](#) ]
23. Zheng, Y. P., Lee, T. T., Lai, K. K., Yip, B. H., Zhou, G. Q., Jiang, W. W., Cheung, J. C., Wong, M. S., Ng, B. K., Cheng, J. C., & Lam, T. P. (2016). A reliability and validity study for Scolioscan: a radiation-free scoliosis assessment system using 3D ultrasound imaging. *Scoliosis and spinal disorders*, 11, 13. <https://doi.org/10.1186/s13013-016-0074-y>. [ [Links](#) ]
24. Fleiss, J. L., Nee, J. C. M., Landis, J. R. (1979). Large sample variance of Kappa in the case of different sets of rates. *Psychology Bull*, 86, 974-977. [ [Links](#) ]
25. Ohrt-Nissen, S., Cheung, J., Hallager, D. W., Gehrchen, M., Kwan, K., Dahl, B., Cheung, K., & Samartzis, D. (2017). Reproducibility of thoracic kyphosis measurements in patients with adolescent idiopathic scoliosis. *Scoliosis and spinal disorders*, 12, 4. <https://doi.org/10.1186/s13013-017-0112-4>. [ [Links](#) ]
26. Ng, S. Y., & Bettany-Saltikov, J. (2017). Imaging in the Diagnosis and Monitoring of Children with Idiopathic Scoliosis. *The open orthopaedics journal*, 11, 1500-1520. <https://doi.org/10.2174/1874325001711011500>. [ [Links](#) ]
27. Alrehily, F., Hogg, P., Twiste, M., Johansen, S., & Tootell, A. (2019). Scoliosis imaging: An analysis of radiation risk in the CT scan projection radiograph and a comparison with projection radiography and EOS. *Radiography (London, England: 1995)*, 25(3), e68-e74. <https://doi.org/10.1016/j.radi.2019.02.005>. [ [Links](#) ]
28. Hresko, M. T., Mesiha, M., Richards, K., & Zurakowski, D. (2006). A comparison of methods for measuring spinal motion in female patients with adolescent idiopathic scoliosis. *Journal of pediatric orthopedics*, 26(6), 758-763. <https://doi.org/10.1097/01.bpo.0000242432.73563.63>. [ [Links](#) ]
29. Fortin, C., Feldman, D. E., Cheriet, F., & Labelle, H. (2010). Validity of a quantitative clinical measurement tool of trunk posture in idiopathic scoliosis. *Spine*, 35(19), E988-E994. <https://doi.org/10.1097/BRS.0b013e3181cd2cd2>. [ [Links](#) ]
30. Knott, P., Lonner, B., Smith, M., Frommeyer, E., & Ren, Y. (2016). Measuring anterior trunk deformity in scoliosis: development of asymmetry parameters using surface topography (a pilot study). *Scoliosis and spinal disorders*, 11(Suppl 2), 32. <https://doi.org/10.1186/s13013-016-0096-5>. [ [Links](#) ]
31. Frerich, J. M., Hertzler, K., Knott, P., & Mardjetko, S. (2012). Comparison of radiographic and surface topography measurements in adolescents with idiopathic scoliosis. *The open orthopaedics journal*, 6, 261-265. <https://doi.org/10.2174/1874325001206010261>. [ [Links](#) ]
32. Guo, J., Liu, Z., Lv, F., Zhu, Z., Qian, B., Zhang, X., Lin, X., Sun, X., & Qiu, Y. (2012). Pelvic tilt and trunk inclination: new predictive factors in curve progression during the Milwaukee bracing for adolescent idiopathic

scoliosis. *European spine journal: official publication of the European Spine Society, the European Spinal Deformity Society, and the European Section of the Cervical Spine Research Society*, 21(10), 2050-2058. <https://doi.org/10.1007/s00586-012-2409-6>. [ [Links](#) ]

33. Blommestein, A. S. V., Lewis, J. S., Morrissey, M. C., MacRae, S. (2012). Reability of measure thoracic kyphosis angle, lumbar lordosis angle and straight leg raise with an inclinometer. *Open Spine J*, 4,10-15. [ [Links](#) ]

34. Branchini, M., Del Vecchio, A., Gigliotti, C. R., Loria, A., Zerbi, A., & Calandrino, R. (2018). Organ doses and lifetime attributable risk evaluations for scoliosis examinations of adolescent patients with the EOS imaging system. *La Radiologia medica*, 123(4), 305-313. <https://doi.org/10.1007/s11547-017-0828-5>. [ [Links](#) ]

<sup>1</sup>Corresponding author: Profa. Dra. Ana Paula Ribeiro Email: [apribeiro@alumni.usp.br](mailto:apribeiro@alumni.usp.br) or [anapribeiro@prof.unisa.br](mailto:anapribeiro@prof.unisa.br) ORCID: <https://orcid.org/0000-0002-1061-3789>


<sup>2</sup>University Santo Amaro, School of Medicine, Biomechanics and Musculoskeletal Rehabilitation Laboratory, Health Science Post-Graduate Department, São Paulo, Brazil. R: Professor Enéas de Siqueira Neto, 340, Campus I - São Paulo - SP, Brazil, CEP:04829-900. Phone: 55 11 99905-8231.

<sup>3</sup>Fuente: DeCS (Descriptores en Ciencias de la Salud)

<sup>4</sup>Source: MeSH (Medical Subject Headings)

Received: April 24, 2022; Accepted: July 14, 2022

Corresponding author: Prof<sup>a</sup>. Dr<sup>a</sup>. Ana Paula Ribeiro Email: [apribeiro@alumni.usp.br](mailto:apribeiro@alumni.usp.br) or [anapribeiro@prof.unisa.br](mailto:anapribeiro@prof.unisa.br) ORCID: <https://orcid.org/0000-0002-1061-3789>

 [Creative Commons License](#) This is an open-access article distributed under the terms of the Creative Commons Attribution License

---

**Apdo. 187-3007 San Joaquín de Flores , Heredia Costa Rica, San Joaquin de Flores, Heredia, CR, 187-3007, 2277-4128**

 e-Mail

[cabarca@racsa.co.cr](mailto:cabarca@racsa.co.cr)